CLEAR CELL ADENOCARCINOMA OF THE CERVIX IN A YOUNG, SEXUALLY NAIVE, AND DES-UNEXPOSED WOMAN: A CASE REPORT

F.O. Sarimiye[1], D.J. Obi[2], F.O. Okpoju[2], A.A. Ekpe[3], M.A. Ajani[4], O.A. Awolude[5]

1. Department of Radiation Oncology, University of Ibadan and University College Hospital, Ibadan, Nigeria
2. Department of Radiation Oncology, University College Hospital, Ibadan, Nigeria
3. Department of Radiology, University College Hospital, Ibadan, Nigeria
4. Department of Pathology, University of Ibadan and University College Hospital, Ibadan, Nigeria
5. Department of Gynae-oncology, University of Ibadan and University College Hospital, Ibadan, Nigeria

Correspondence:
Dr. D.J. Obi
Department of Radiation Oncology,
University College Hospital,
Ibadan.
Email: dalujobi@gmail.com

Submission Date: 10th April, 2026
Date of Acceptance: 6th July, 2026
Publication Date: 31st Aug., 2026

Copyright Statement
The copyright of this manuscript is vested in this journal and in its publisher, the Association of Resident Doctors, University College Hospital, Ibadan.

This article is licensed under the Creative Common Attribution-Non Commercial License 3.0 (CC BY-NC 3.0).

ABSTRACT

Background: **Clear cell adenocarcinoma of the cervix (CCAC) is a rare subtype of adenocarcinoma of the cervix. While it has been associated with intrauterine exposure to diethylstilbestrol (DES), it can, however, occur in women with no history of DES exposure. The commonest clinical presentation is abnormal vaginal bleeding. It's rarity may contribute to delayed diagnosis.**

Case report: **We report the case of a 25-year-old sexually naïve female with no history of DES exposure who presented with abnormal vaginal bleeding. Examination revealed a craggy cervical mass extending to the upper two-thirds of the vagina with parametrial involvement. Histopathological examination confirmed clear cell adenocarcinoma of the cervix, and imaging demonstrated a heterogeneously enhancing cervical mass. She was staged as FIGO IIB and scheduled for definitive concurrent chemoradiotherapy in accordance with NCCN guidelines. However, financial constraints resulted in loss to follow-up, and she re-presented one year later with pulmonary metastases.**

Conclusions: **A high index of suspicion is required in considering CCAC in the differential diagnosis of abnormal vaginal bleeding, even in women not exposed to diethylstilbestrol. Delays in early detection and treatment protocols can lead to disease progression and poorer outcomes.**

Keywords: Clear cell adenocarcinoma, Cervix, Diethylstilbestrol, Chemoradiation.

INTRODUCTION

Cervical cancer is a significant public health concern, particularly in low and middle-income countries (LMICs) where there is limited access to early screening and timely interventions.[1,2]

Globally, it is the fourth most common cancer among women, with an annual mortality rate of 348,000 (3,4). In Nigeria, according to Global Cancer Observatory (GLOBOCAN) 2022, cervical cancer is the second most common cancer in women, with an estimated incidence of 13,676 cases and a mortality rate of 51.8% annually.[4,5,6]

Squamous cell carcinoma (SCC) accounts for the commonest histological type, while Clear cell adenocarcinoma of the cervix (CCAC) is a rare histological variant and this accounts for 4-9% of adenocarcinoma of the cervix (7).

A hospital-based study in University College Hospital, South-West Nigeria, reported that SCC constitutes 88.7% of cervical cases, while 18% were adenocarcinomas.[8]

Adenocarcinoma histology has been associated with poor survival outcomes in all stages.[9]

Clear cell adenocarcinoma of the cervix has been linked to intrauterine exposure to diethylstilbestrol (DES), which is a synthetic oestrogen taken to prevent miscarriage before 1971.[10] Approximately 60% of CCAC cases are linked to intrauterine exposure to DES, although this occurrence is rare. Only about 1in 1,000 women exposed to DES in utero are affected.[11] This group has a 40-fold higher risk of developing CCAC than those not exposed.

Patient commonly present with abnormal vaginal bleeding. They can also present with abnormal vaginal discharge and abdominal pain.[12]

We report a case of a 25-year-old woman, sexually naïve, diagnosed with CCAC with no history of intrauterine DES exposure.

CASE PRESENTATION

A 25-year-old undergraduate was referred to the gynae-oncology unit with a one-year history of vaginal bleeding. The bleeding was said to be heavy and was associated with foul-smelling vaginal discharge.

There was no known family history of breast, endometrial or ovarian cancer. The patient had no intrauterine exposure to DES and had not attained coitarche. She had no history of tobacco use but reported occasional alcohol consumption.

On examination, she was found to be anaemic with Hb of 5g/dl. Cervical examination revealed hymenal remnants consistent with carunculae myrtiformes. A 6x8 cm craggy cervical mass that bled on contact was palpated, extending to the upper two-thirds of the vagina with parametrial involvement.

Abdominopelvic CT scan revealed a well-encapsulated heterogeneously enhancing solid mass measuring 5.1 x 8.3 x 7.1cm in the uterine cervix with mass effect on the bladder and rectum. She was staged as FIGO IIB

Examination under anaesthesia and cervical biopsy were performed. Histology showed a malignant epithelial neoplasm composed of moderately pleomorphic cells disposed in sheets and nets, infiltrating the stroma. The component tumour cells had large hyperchromatic to vesicular nuclei with occasional prominent nucleoli and abundant clear cytoplasm. Extensive areas of necrosis were noted. A histologic diagnosis of clear cell carcinoma was made. (Figure 1)

She was transfused and referred to the Radiation Oncology department for chemoradiation. However, the patient was lost to follow-up due to unaffordable costs at the time. The hospital's social work team was contacted, and the patient was advised to see them. Nonetheless, she sought alternative non-medical care and looked for funding for her treatment. The patient was given a brief appointment but defaulted until she re-presented a year later with complaints of progressively foul-smelling vaginal discharge. On examination, a hard, irregular mass extending to the lower third of the vagina was palpated. She was again anaemic, with a haemoglobin level of 5.3 g/dL. CA-125 was elevated at 28.8 U/mL.

Chest and abdominopelvic CT-scan revealed lung lesions measuring 9.2 x 6.9 mm in the apicoposterior segment of the left upper lobe, smaller non-enhancing nodules in the apical segment and lateral segment of the right upper and lower lobes and hepatic deposit in segment IVb of the liver.

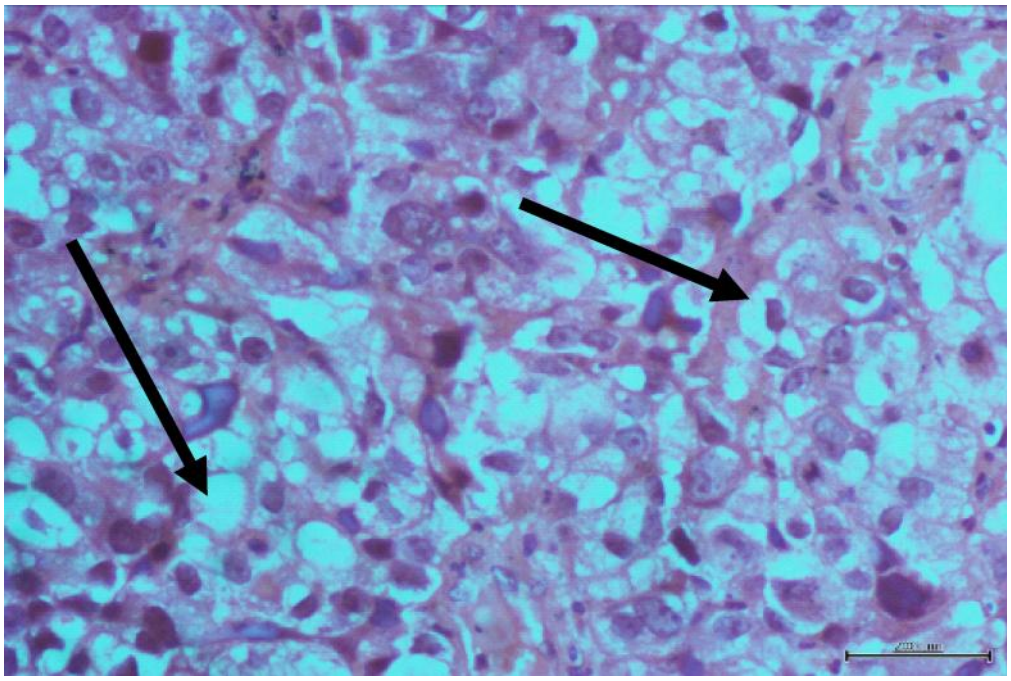

Figure 1: Photomicrograph showing clear cell carcinoma of the cervix. The component tumour cells have hyperchromatic nuclei and abundant clear cytoplasm (arrows). (haematoxylin and eosin stains, ×400)

Pelvic imaging showed a well-encapsulated, heterogeneously enhancing solid cervical mass with a mild interval increase in size, now measuring 6.4 x 7.2 x 9.9 cm. She was restaged as FIGO stage IVB. (Figure 2)

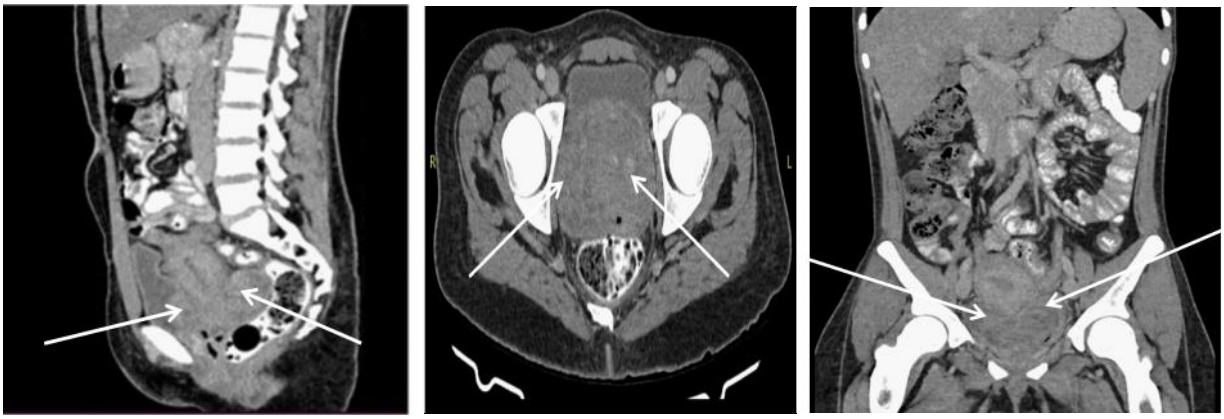

A: Sagittal post contrast B: Axial post contrast C: Coronal post-contrast.

Figure 2: Abdominopelvic computed tomography (CT) images obtained at the patient's re-presentation one year after the initial diagnosis, demonstrating clear cell adenocarcinoma of the cervix.
(A) Heterogeneously enhancing circumferential cervical soft tissue mass seen extending into the rectouterine and vesicouterine pouches (White arrow). (B) Bulky and heterogeneously enhancing cervical mass. (C) Heart-shaped, infiltrative, heterogeneously enhancing cervical mass demonstrating parametrial extension.

She was transfused and counselled on the need to commence palliative systemic therapy with Cisplatin/ Paclitaxel, including immunotherapy, but unfortunately, she could not afford the treatment at the time. The hospital's social work unit was involved, and they are currently soliciting financial support on the patient's behalf.

As of the time of this report, the patient is stable.

DISCUSSION

Clear cell carcinoma of the cervix (CCAC) is a rare malignancy that has been historically linked to in utero exposure to diethylbestrol (DES), a synthetic oestrogen prescribed to pregnant women between the 1940s and 1971 to prevent miscarriage, labour-related complications, before it was banned.[13]

Clear cell carcinoma of the cervix has a bimodal age distribution, with the first peak occurring in women aged 17-37 years and the second in women aged 44-88 years. The median age of onset in DES-related CCAC is 19 years, compared with 51 years in sporadic (non-DES-related) cases.[14]

Several cases of CCAC have been reported in women with no known DES exposure, as illustrated by this case.

The aetiopathogenesis of sporadic CCAC remains unclear, and it is typically not associated with the risk factors of squamous cell carcinoma of the cervix, such as increasing age, multiple sexual partners, smoking, low socioeconomic status, contraceptive use and human papillomavirus (HPV) infection.[15,16,7]

The most common presenting symptom is abnormal vaginal bleeding, which is frequently misdiagnosed as dysfunctional uterine bleeding or a benign vaginal lesion[17,18,19]

In this case, the patient, a 25-year-old sexually naïve woman with no history of DES exposure, presented with advanced-stage CCAC. Her symptoms of abnormal vaginal bleeding and foul-smelling discharge were consistent with a malignancy. Still, the absence of coitache and the rarity of CCAC might have contributed to the delay in diagnosis.

Management of CCAC typically follows that of cervical squamous cell carcinoma, with surgical intervention preferred in early stages and concurrent chemoradiation for stages IB – IVA.[20]

In this patient, surgery was not feasible due to the advanced stage of the disease. The National Comprehensive Cancer Network (NCCN) guideline prioritises systemic treatment with immunotherapy in such cases[21], and she was being prepared for this treatment modality

Previous studies have reported that the prognostic factors of CCAC include advanced age, metastasis, tumour size, nuclear atypia and mitotic activity.[15,22]

Regrettably, the patient was lost to follow-up, which likely contributed to disease progression, including pulmonary and hepatic metastasis, an indicator of poor prognosis.[23] Thomas *et al.* reported three-year survival rates as high as 91% in early-stage (stage I-IIA) cases, compared to just 22% in advanced-stage cases (stage III-IV).[24]

Patient presented at a locally advanced stage, which could have been treated with chemoradiation with a potential good outcome, but due to a lack of funds, she defaulted on care and sought alternative treatment. In addition to the treatment recommended, early integration of palliative care is recommended for patients with locally advanced cervical cancer.[25] Palliative care plays an important role in optimising symptom control, addressing financial and logistical barriers to treatment, providing psychosocial support, and improving quality of life throughout the treatment of the disease.

Following disease progression with pulmonary metastases, the patient would benefit from specialist palliative care to manage cancer-related symptoms and facilitate advance care planning.

Improving outcomes for patients with cervical cancer in resource-limited settings requires more than timely diagnosis and treatment.[26] Strategies should include strengthening access to health insurance schemes through the National Health Insurance Authority (NHIA) and state health insurance schemes,[27] expanding government-supported cancer financing programmes such as the Cancer Health Fund (CHF) and the newer Social Determinants of Health Fund for cancer patients[28], enhancing hospital-based medical social welfare services for vulnerable patients, and implementing effective patient navigation and follow-up systems to reduce treatment interruption and loss to follow-up. Continued investment in specialised oncology centres and equitable access to comprehensive cancer care are also essential to improve treatment completion, survival, and quality of life.[29,30]

CONCLUSION

This case highlights the rare occurrence of clear cell adenocarcinoma of the cervix (CCAC) in a young, sexually naïve woman without known exposure to diethylstilboestrol (DES).

CCAC should be an important differential diagnosis in women presenting with persistent abnormal vaginal bleeding, even in the absence of recognised risk factors or a history of DES exposure. Delayed presentation, financial constraints, and loss to follow-up contributed to disease progression from potentially curable FIGO stage IIB disease to metastatic disease, emphasising the impact of barriers to cancer care in resource-limited settings.

A high index of suspicion, prompt histopathological diagnosis, timely initiation of guideline-directed treatment, early integration of palliative care where appropriate, and strengthened patient follow-up systems are needed to improve care.

To achieve a decreased cervical cancer mortality and morbidity when diagnosed in our environment, a subsidised fee could be given to these kinds of patients and a policy to offer follow-up even if patients will not accept the recommended treatment, especially when seen in the younger population.

Acknowledgements

I would like to thank all the authors who made the writing of this manuscript possible. Your dedication was quite inspiring.

Author contributions

Writing—original draft: D.O

Data curation: F.O, A.E, M.A

Reviewing: F.S, O.A

Declarations

Author agreement: All authors listed in the manuscript are aware of and agree to the submission of this manuscript.

Informed consent: This study obtained the informed consent of the patient.

Funding: The authors received no funding for this study

Conflict of interest: The authors declare that they have no conflicts of interest

Data availability: The data generated during and/or analysed during the study are available from the corresponding author upon reasonable request.

REFERENCES

1. **Raheem N,** Dahiru AMC, Jangle NL, Sule AA. Histopathological pattern of cervical cancers in Yola, North-Eastern Nigeria. Journal of

Diagnostic and Academic Pathology. 2024 Jul;1(2):55–60.
2. **Lawson O,** Ameyan L, Tukur Z, *et al.* Cervical cancer screening outcomes in public health facilities in three states in Nigeria. BMC Public Health. 2023 Sep 1;23(1):1688.
3. **Stelzle D,** Tanaka LF, Lee KK, *et al.* Estimates of the global burden of cervical cancer associated with HIV. Lancet Glob Health. 2021 Feb;9(2): e161–169.
4. **Bray F,** Laversanne M, Sung H, *et al.* Global cancer statistics 2022: GLOBOCAN estimates of incidence and mortality worldwide for 36 cancers in 185 countries. CA Cancer J Clin. 2024 Apr 4;74 (3):229–263.
5. **Ola IO,** Okunowo AA, Habeebu MY, Miao Jonasson J. Clinical and non-clinical determinants of cervical cancer mortality: A retrospective cohort study in Lagos, Nigeria. Front Oncol. 2023 Feb 16;13:1105649.
6. **Usman A,** Bello SS, Abdurrahman A, *et al.* A histopathological review of gynaecological malignancies in Katsina state North-Western Nigeria. Ecancermedicalscience. 2024 Aug 29;18: 1750.
7. **Mathew Thomas V,** Alexander SA, Hadfield MJ, Vredenburgh J. A Rare Case of Clear Cell Adenocarcinoma of the Cervix with No Intrauterine Diethylstilbestrol Exposure. Cureus. 2020 Apr 23;12(4):e7796.
8. **Awolude OA,** Oyerinde SO. Invasive cervical cancer in ibadan: socio-sexual characteristics, clinical stage at presentation, histopathology distributions and hiv status. Afr J Infect Dis. 2019;13(1):32–38.
9. **Hong S-S,** Li Y, Lin Y-Y, *et al.* Disparities in Survival Outcomes Between Locally Advanced Cervical Squamous Cell Carcinoma and Adenocarcinoma Treated with Chemoradiotherapy. Int J Womens Health. 2024 Mar 6;16:401–410.
10. **Huo D,** Anderson D, Palmer JR, Herbst AL. Incidence rates and risks of diethylstilbestrol-related clear-cell adenocarcinoma of the vagina and cervix: Update after 40-year follow-up. Gynecol Oncol. 2017 Sep;146(3):566–571.
11. **Conlon JL.** Diethylstilbestrol: Potential health risks for women exposed in utero and their offspring. JAAPA. 2017 Feb;30(2):49–52.
12. **Cue L,** Martingano DJ, Mahdy H. Clear cell carcinoma of the cervix. StatPearls. Treasure Island (FL): StatPearls Publishing; 2026.
13. DES Exposure: Questions and Answers | American Cancer Society [Internet]. [cited 2025 Apr 19]. Available from: https://www.cancer.org/cancer/risk-prevention/medical-treatments/des-exposure.html
14. **Stolnicu S,** Karpathiou G, Guerra E, *et al.* Clear Cell Carcinoma (CCC) of the Cervix Is a Human Papillomavirus (HPV)-independent Tumor Associated With Poor Outcome: A Comprehensive Analysis of 58 Cases. Am J Surg Pathol. 2022 Jun 1;46(6):765–773.
15. **Liu Z,** Li J, Gu H, *et al.* Clear cell adenocarcinoma of uterine cervix: A single institution retrospective experience. Front Oncol. 2020 Nov 13;10:532748.
16. **Pirog EC,** Lloveras B, Molijn A, *et al.* HPV prevalence and genotypes in different histological subtypes of cervical adenocarcinoma, a worldwide analysis of 760 cases. Mod Pathol. 2014 Dec;27(12):1559–1567.
17. **Adams T,** Denny L. Abnormal vaginal bleeding in women with gynaecological malignancies. Best Pract Res Clin Obstet Gynaecol. 2017 Apr;40:134–147.
18. **Tournaire M,** Gondry J, Mauny L, *et al.* Late cervical and vaginal clear cell adenocarcinoma in women exposed in utero to diethylstilbestrol: Evaluation and screening. J Gynecol Obstet Hum Reprod. 2023 Oct;52(8):102630.
19. **Usman MA,** Otene SA. Clinicopathologic features of cervical cancer patients seen in a comprehensive cancer centre in north-western nigeria. OJMR. 2021 Jun 1;2(1).
20. Cervical Cancer - Guidelines Detail [Internet]. [cited 2025 Apr 21]. Available from: https://www.nccn.org/guidelines/guidelines-detail?category=1&id=1426
21. **Abu-Rustum NR,** Yashar CM, Arend R, *et al.* NCCN guidelines® insights: cervical cancer, version 1.2024. J Natl Compr Canc Netw. 2023 Dec;21(12):1224–1233.
22. **Yang L,** Zheng A, Zhang X, *et al.* Clear cell carcinoma of the uterine cervix: A clinical and pathological analysis of 47 patients without intrauterine diethylstilbestrol exposure. Int J Gynecol Cancer. 2017 Jun;27(5):1009–1014.
23. **Chen X,** Chen L, Zhu H, Tao J. Risk factors and prognostic predictors for Cervical Cancer patients with lung metastasis. J Cancer. 2020 Aug 8;11(20):5880–5889.
24. **Thomas MB,** Wright JD, Leiser AL, *et al.* Clear cell carcinoma of the cervix: a multi-institutional review in the post-DES era. Gynecol Oncol. 2008 Jun;109(3): 335–339.
25. **Dey T,** Mukerjee A, Rai B, *et al.* Early integration of palliative care in cervical cancer: Experiences from a pilot study. J Family Med Prim Care. 2023 Feb 28;12(2):366–370.
26. **Okolie EA,** Beek K, Patel B, *et al.* Cervical cancer prevention and control in Nigeria: mapping and

review of policies. Health Policy Plan. 2025 Sep 17;40(8):931–942.
27. National Health Insurance Authority – Financial Access To Healthcare For All Nigerians [Internet]. [cited 2026 Jul 1]. Available from: https://www.nhia.gov.ng/
28. Federal govt launches fund to support cancer patients, pledges N50 million [Internet]. [cited 2026 Jun 30]. Available from: https://www.premiumtimesng.com/health/health-news/888523-federal-govt-launches-fund-to-support-cancer-patients-pledges-n50-million.html?tztc=1
29. **Ogunniyi TJ,** Fatokun BS, Isah KO, *et al.* Current status of cancer diagnosis and treatment in nigeria. Health Sci Rep. 2025 Jun;8(6):e70877.
30. FMH&SW & NSIA Join Forces to Expand Access to Oncology Care through the Oncology Initiative / NSIA [Internet]. [cited 2026 Jun 30]. Available from: https://nsia.com.ng/fmhsw-nsia-join-forces-to-expand-access-to-oncology-care-through-the -oncology-initiative.