

POSTERIOR UVEAL EFFUSION POST TRABECULECTOMY IN UNILATERAL INFANTILE GLAUCOMA: A CASE REPORT AND MANAGEMENT CHALLENGES

T.F. Sarimiye¹, A.S. Ata², and A.A. Olagunju²

1. Department of Ophthalmology, University of Ibadan and University College Hospital, Ibadan, Nigeria.
2. Department of Ophthalmology, University College Hospital, Ibadan, Nigeria.

Correspondence:

Dr. A.S. Ata

Department of Ophthalmology,
University College Hospital,
Ibadan.

Email: dranibeata@yahoo.com

ABSTRACTS

Choroidal effusion is an abnormal collection of fluid within the suprachoroidal potential space. It is a common complication following glaucoma filtering surgeries such as trabeculectomy. It is a clinical diagnosis that sometimes goes undetected or unreported, except when symptomatic. Reported incident rates is 7.9 – 18.8% for serous effusions and 0.7 – 3% for haemorrhagic effusions. This report aims to highlight a case of choroidal effusion after trabeculectomy and its management challenges.

Case Report: A seven year old boy presented to our facility with history of cloudy appearance of the right eye of five years duration. He was diagnosed with right infantile glaucoma. Intraocular pressures (IOP) were 44mmHg and 18mmHg right and left eyes respectively. Patient subsequently had right trabeculectomy. He developed hypotony at post-operative day two and a right choroidal effusion was noticed at post-operative day four. As a result of this, he initially had a right anterior chamber reformation with ocular viscoelastic on day seven. Later, a compression suture over the bleb and sclerostomy was performed 11 days post initial surgery. Choroidal effusion progressively regressed post-operatively and completely resolved at day five post-sclerostomy and effusion drainage.

Conclusion: Choroidal effusion is a common complication after trabeculectomy in which conservative management results in resolution. However, when conservative management fails, surgical intervention should not be delayed to maximize good outcome.

Keywords: Choroidal effusion, Glaucoma, Trabeculectomy.

CASE REPORT

A 7 year old male presented on account of whitish speck noted in the right eye of about 5 years duration. There was a history of the right eye being slightly bigger than the left as well as poor vision in the right eye. There was no history of eye protrusion, abnormal skin pigmentation or seizures. There was no previous ocular surgeries, nil significant medical illnesses or previous hospitalization and no family history of glaucoma.

Visual acuity was count fingers (CF) right eye and 6/5 left eye. Manifest refraction was +0.50DS/-2.75DC/80 right eye and +0.25DS left eye. A relative afferent pupillary defect (RAPD) was noted on the right eye. Applanation intraocular pressures were 44mmHg and 18mmHg in the right and left eye respectively.

Slit lamp examination on the right eye showed a buphthalmic globe, Haab's striae on the cornea with corneal diameter of 16.5 x 15.5mm, deep anterior chamber, round and sluggishly reactive pupil with RAPD, clear lens and cupped disc with a cup-to-disc

(CDR) 1.0. Finding in the left eye were essentially normal with a pink disc of CDR 0.4.

An assessment of right infantile glaucoma was made and was temporarily commenced on anti-glaucoma medications (timolol and dorzolamide combination) for the right eye. He subsequently had right trabeculectomy with Mitomycin-C (MMC) under general anaesthesia. Notable intraoperative event was sudden shallowing of the anterior chamber upon entry. Postoperatively, he developed hypotony (an IOP of 0mmHg) with a huge bleb on the 2nd post-operative day and shallow anterior chamber with choroidal detachment observed on the 4th post-operative day (Fig. 1).

An assessment of right overfiltration with choroidal effusion status post trabeculectomy was made. He initially had conservative management which included maximum cycloplegia and reduction of the frequency of topical steroid. This was to allow for deepening of the anterior chamber by pulling of the iris-lens

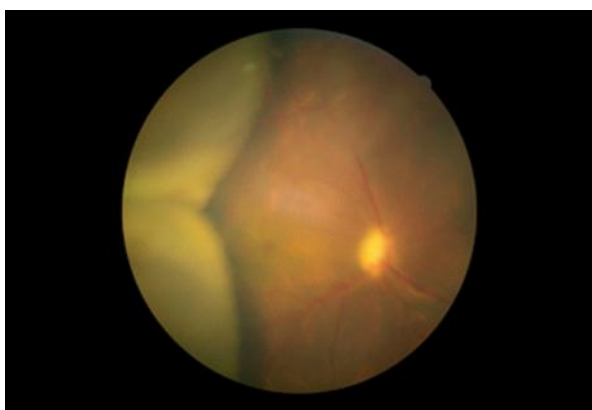


Figure 1: Fundus photograph of the right eye post-operative day 4 showing choroidal effusion on the temporal aspect just sparing the fovea.

diaphragm back and for some healing around the scleral flap and bleb to reduce the overfiltration. Upon failed conservative management, he had a right anterior chamber reformation with viscoelastic under general anaesthesia on post-operative day 7 to augment the

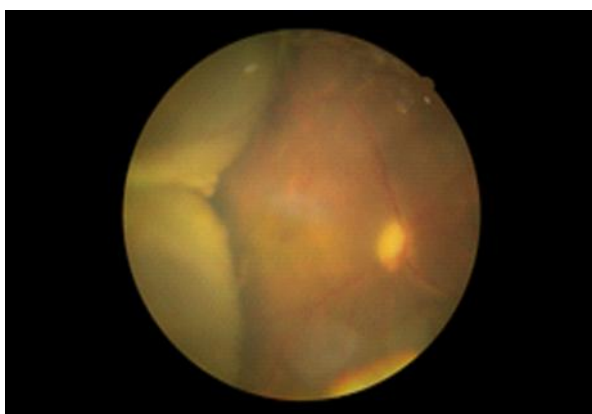


Figure 2a: Fundus picture of the right eye on post-operative day 7 with increased height and extension of the choroidal effusion.

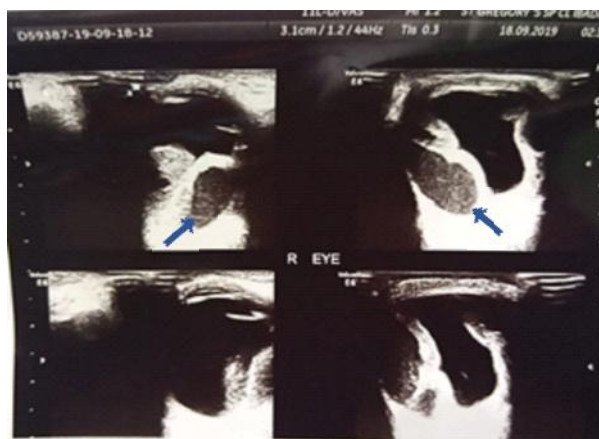


Figure 2b: Ultrasound of the right eye showing the choroidal effusion as indicated by the blue arrows. Axial length was 23mm and 24mm for the right and left eye respectively.

conservative management. However, effusion worsened progressively, with vision of light perception (LP) and hypotony persisted as shown in figure 2 (a and b).

At the 11th day post-trabeculectomy, patient eventually had a right compression suture, repeat anterior chamber reformation with viscoelastic and sclerostomy with drainage of effusion under general anaesthesia.

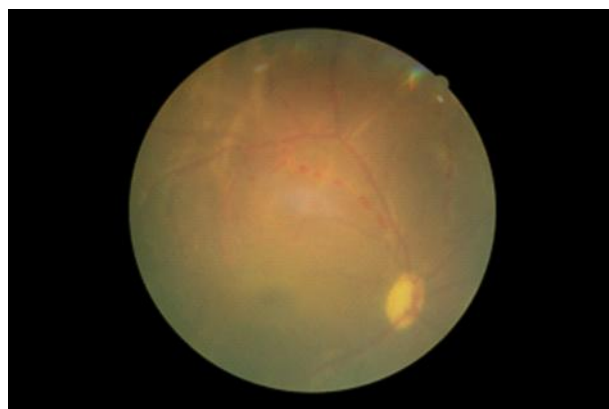


Figure 3: Right eye fundus picture showing resolved choroidal effusion with completely flat retina 1 week post sclerostomy and effusion drainage.

Intraoperative findings include thick tenon capsule and sclera (which was unusual for an enlarged globe) and straw coloured suprachoroidal fluid was drained. Effusion resolved post-operatively with visual acuity of CF and the retina remained flat as shown in figure 3.

COMMENT

Choroidal effusions are aberrant collections of fluid within the suprachoroidal potential space. It is also referred to as posterior uveal effusion. The most common risk factor for choroidal effusions is glaucoma surgery in the setting of overfiltration or a bleb leak.¹ Amongst several risk factors that can predispose to choroidal effusion, notable risk factors seen in our patient were overfiltration, intraoperative antimetabolite use (Mitomycin C), sudden drop in IOP during glaucoma surgery², thick scleral and general anaesthesia.³

Uveal effusion syndrome is occasionally associated with a small but normal eye (nanophthalmos). This association was first reported by Brockhurst⁴ in 1974 in five nanophthalmic patients who underwent glaucoma surgery for either acute or chronic angle closure glaucoma. The thickened sclera seen in this anomaly may lead to partial obstruction of the vortex veins leading to the choroidal effusions. Our patient

had thick sclera in keeping with nanophthalmic eye as against a straightforward buphthalmos. So, are we dealing with nanophthalmos in our patient? Nanophthalmos usually present as a bilateral and symmetrical eye condition, thus it was expected for our patient to have a small left eye also. However, B-scan performed post-trabeculectomy in our case showed antero-posterior diameter was 23mm and 24mm in the right and left eye respectively which were within normal range. Hence, are we dealing with the very unlikely scenario of a unilateral nanophthalmos? If we are not dealing with unilateral nanophthalmos, then the axial length being unexpectedly less in the right buphthalmic eye compared to the left may be explained by the reduction in the antero-posterior diameter due to the effusion at the time of measurement. Unfortunately there was no axial length measurement before the initial surgery, so we cannot ascertain if we are dealing with unilateral nanophthalmos or not. Choroidal effusion could be serous or haemorrhagic. In our case, straw coloured fluid was drained from the suprachoroidal space hence effusion was serous. Serous choroidal effusions usually follow a more benign course that often results in resolution with conservative therapy and no significant reduction in best corrected visual acuity⁵, however conservative management failed in our patient. In fact, effusion progressively worsened and drainage had to be performed on the 11th post-operative day to achieve resolution.

The incidence of choroidal effusion varies depending on the surgical technique. The reported rate of postoperative serous choroidal effusion ranges from 7.9 to 18.8% following trabeculectomy.^{6,7,8,9} Some of the newer glaucoma surgeries (such as the trabectome, iStent, canaloplasty and GATT) offer lower rates of postoperative choroidals. However, trabeculectomy and tube-shunt procedures continue to be the most frequently utilized because of their efficacy in IOP reduction.

Conservative management of serous effusion should always be attempted but elective surgical intervention should not be delayed if conservative management fails.

REFERENCES

1. <https://www.aao.org/eyenet/article/choroidal-effusions>.
2. **Healey PR**, Herndon L, Smiddy W. Management of suprachoroidal hemorrhage. *J Glaucoma* 2007; 16:577–579.
3. **Chu TG**, Green RL. Suprachoroidal hemorrhage. *Surv Ophthalmol* 1999; 43:471–486.
4. **Brockhurst RJ**. Nanophthalmos with uveal effusion: new clinical entity. *Trans Am Ophthalmol Soc* 1974;72:371–403.
5. **Altan C**, Ozturker C, Bayraktar S, *et al*. Posttrabeculectomy choroidal detachment: not an adverse prognostic sign for either visual acuity or surgical success. *Eur J Ophthalmol* 2008; 18:771–777.
6. **Jampel HD**, Musch DC, Gillespie BW, *et al*. Perioperative complications of trabeculectomy in the collaborative initial glaucoma treatment study (CIGTS). *Am J Ophthalmol* 2005; 140:16–22.
7. **Gedde SJ**, Schiffman JC, Feuer WJ, *et al*. Treatment outcomes in the Tube Versus Trabeculectomy (TVT) study after five years of follow-up. *Am J Ophthalmol* 2012; 153:789–803; e2.
8. **Gedde SJ**, Herndon LW, Brandt JD, *et al*. Postoperative complications in the Tube Versus Trabeculectomy (TVT) study during five years of follow-up. *Am J Ophthalmol* 2012; 153:804–814; e1.
9. **Haga A**, Inatani M, Shobayashi K, *et al*. Risk factors for choroidal detachment after trabeculectomy with mitomycin C. *Clin Ophthalmol (Auckland, NZ)* 2013; 7:1417–1421.