

## CLINICO-HISTOPATHOLOGIC PRESENTATION OF A NIGERIAN CHILD WITH TORSION OF A TESTICULAR APPENDAGE: A CASE REPORT

K.I Egbuchulem<sup>1</sup>, A. A Ishola<sup>2</sup>, C.O Onwurah<sup>3</sup>.

1. Division of Paediatric Surgery, Department of Surgery, University College Hospital, Ibadan.
2. Division of General Surgery, Department of Surgery, University of Ibadan, Ibadan.
3. Final year Medical Student, College of Medicine, University of Ibadan, Ibadan.

### Correspondence:

**Dr. K. I Egbuchulem**

Division of Paediatric Surgery,  
Department of Surgery,  
University College Hospital,  
Ibadan.

*Submission Date: 17th July, 2023*

*Date of Acceptance: 25th Dec., 2024*

*Publication Date: 31st Dec., 2024*

### ABSTRACT

**Torsion of hydatid of Morgagni (appendix testis) is one of the causes of acute scrotum. However, it can be distinguished from testicular torsion by its insidious onset and localizable tenderness. In addition, colour doppler ultrasonography has characteristic findings in torsion of hydatid of Morgagni.**

**We present a case of torsion of hydatid of Morgagni which was of sudden onset, and had clinical features mimicking testicular torsion which warranted immediate scrotal exploration. Intra-operative finding was torsion of appendix testis as against the clinical presentation suggestive of testicular torsion.**

**Acute scrotum being a time dependent emergency may not allow time for doppler ultrasonography which will differentiate torsion of appendix testis from testicular torsion thus preventing unnecessary scrotal exploration.**

### INTRODUCTION

The appendix testis and the appendix epididymis are the two testicular appendages that can also undergo torsion mimicking testicular torsion. The appendix testis or hydatid of Morgagni is a vestigial remnant of the Mullerian duct which is present in about 76 to 83% of testes.<sup>1,2</sup> It is located on the superior pole just between the testis and epididymis, and it is the most common appendage to undergo torsion.<sup>1,2</sup> Torsion of hydatid of Morgagni is a common cause of acute scrotal pain in prepubertal boys.<sup>1-3</sup>

Torsion of hydatid of Morgagni commonly causes pain similar to that of testicular torsion.<sup>4,5</sup> Physical examination in torsion of testicular appendage may reveal a normally appearing scrotum with intact cremasteric reflex and tenderness localized to the upper pole of the testis or epididymis with a palpable localizable mass in the area of maximum tenderness. However, reactive inflammation of surrounding structures may cause a more diffuse pain making torsion of appendix testis indistinguishable from testicular torsion.<sup>6</sup>

Colour doppler ultrasonography is the imaging modality of choice for the evaluation of the acute scrotum in all age groups. Treatment of torsion of a testicular appendage is usually non-operative, and symptoms usually resolve within a week. A scrotal exploration usually is performed when there are doubts about the diagnosis. Scrotal exploration is recommended without delay for a scrotal scan to improve chances of testicular salvage in patients with

very high risk of having of testicular torsion as determined by the Testicular Workup for Ischaemia and Suspected Torsion (TWIST) score.<sup>6</sup> TWIST score is a 7-point tool for evaluating acute scrotal pain. It consists of testicular swelling (2 points), hard testis (2 points), high-riding testis (1 point), absent cremasteric reflex (1 point) and nausea/vomiting (1 point).<sup>7</sup> A score of 5 and above is concerning for testicular torsion for which delays should be avoided, and urgent scrotal exploration recommended.<sup>7,8</sup>

We report a case of torsion of hydatid of Morgagni in 9-year-old Nigerian male who presented with sudden onset acute scrotum.

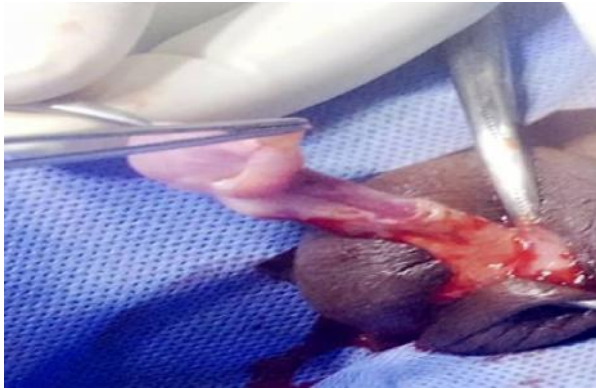
### CASE PRESENTATION

A 9-year-old male presented with a sudden onset left scrotal pain few hours prior to presentation. The pain was dull in nature and relieved transiently by the use of analgesics. There was no history of fall or trauma to the scrotum. There was no history of dysuria, urinary frequency, pus or blood in the urine. He had no history of recent urethral catheterization or previous episode of scrotal pain. There was no associated fever, nausea or vomiting.

At presentation, he was afebrile and well hydrated. His vital signs were normal while genital examination revealed a swollen left hemi-scrotum which was warm and tender. Cremasteric reflex was absent and Prehn sign was negative. He had a TWIST score of 5 (left testicular swelling; 2, absent cremasteric reflex; 1, hard

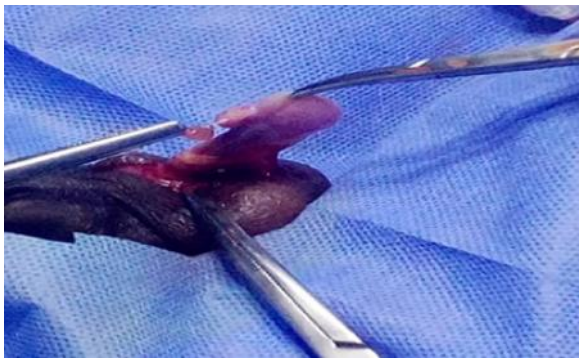left testis; 2) which necessitated immediate scrotal exploration.

Intra-operative finding was an inflamed tiny polypoid tissue in 630° anticlockwise torsion at the superior pole normal left testis close to the groove between the testis and epididymis (Figure 1). The appendage



**Figure 1:** Showing inflamed torsed testicular appendage at the superior pole of the testis close to the groove between the testis and epididymis.

was detorsed, ligated at its base and excised (Figure 2). Scrotal incision was closed with subcuticular vicryl 2/0 stitches, and patient was discharged on 2nd post-operative day. He was seen at surgical outpatient clinic at 2nd post-operative week with no complaints and

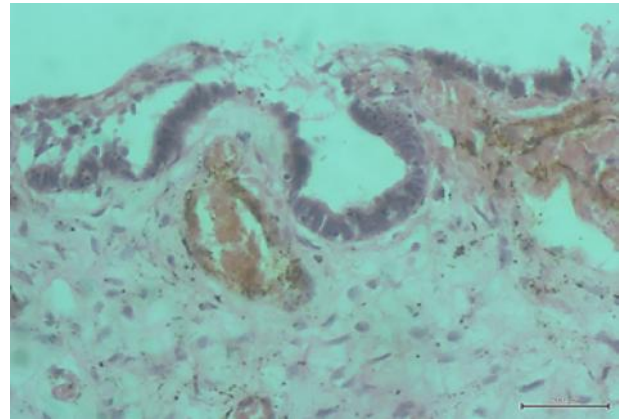


**Figure 2:** Showing the ligated detorsed testicular appendage just before excision



**Figure 3:** Polypoid tissue partly lined by pseudostratified columnar epithelium

satisfactory wound healing. Microscopy of excised surgical specimen revealed sections of polypoid tissue partly lined by pseudostratified columnar epithelium (Figure 3). There were ducts lined by similar pseudostratified epithelium and were within the underlying loose fibromyxoid stroma. Also seen were congested blood vessels. Features are in keeping with an epididymal appendage (Figure 4).



**Figure 4:** Showing ducts lined by pseudostratified epithelium within the underlying loose fibromyxoid stroma. Also seen are congested blood vessels

## DISCUSSION

Colt was the first in 1922 to report a case of torsion of the appendix testis.<sup>9</sup> The hydatid of Morgagni (appendix testis) is the vestigial remnant of the upper end of the müllerian duct corresponding to the fimbriated end of the fallopian duct. It is seen in 76 to 83 per cent of the testes.<sup>1,2,6,10</sup> The actual cause of torsion of testis or its appendage is unknown but may be related to trauma or prepubertal enlargement, and for unexplained reasons it has been found to be commoner during winter.<sup>8</sup>

Torsion of hydatid of Morgagni commonly causes pain similar to that of testicular torsion.<sup>4,5</sup> Physical examination in torsion of testicular appendage may reveal a normally appearing scrotum with intact cremasteric reflex and tenderness localized to the upper pole of the testis or epididymis with a palpable localizable mass in the area of maximum tenderness.<sup>10</sup> Colour Doppler ultrasonography is the imaging modality of choice for the evaluation of the acute scrotum in all age groups. In torsion of hydatid of Morgagni it will typically show normal blood flow to the testicle on the affected side with or without hyperperfusion of the associated epididymis, and an oval avascular lesion with heterogeneous echotexture and posterior enhancement at or close to the upper pole of the testis.<sup>2,11</sup>

Treatment of torsion of a testicular appendage is usually conservative therapy. Conservative management includes bed rest, scrotal elevation, ice, nonsteroidal anti-inflammatory drugs, and analgesics. Symptoms usually resolve in one week. However, in order to improve testicular salvage rates in testicular torsion, it is important to promptly offer scrotal exploration to patients with suspicion of testicular torsion without delay for scrotal ultrasonography.<sup>7</sup> Hence, the TWIST score was developed, and it has been validated to identify patients at high risk of testicular torsion among patients with acute scrotum.<sup>7</sup> Our patient had a score of 5 which raised a suspicion of testicular torsion, and symptoms have been present for hours. Hence, the decision not to delay scrotal exploration for scrotal ultrasonography. Our patient's left hemiscrotal swelling and tenderness may have resulted from reactive inflammatory changes of scrotal tissue due to the inflamed torsed hydatid of Morgagni. Also, the absence of cremasteric reflex on the left side probably due to the foregoing contributed to the high TWIST score which necessitated immediate exploration.

## CONCLUSION

Torsion of hydatid of Morgagni is a common cause of acute scrotum which may be distinguished clinically from testicular torsion. However, presentation may mimic testicular torsion necessitating emergent scrotal exploration over scrotal ultrasound as seen in this reported case. This leads to unnecessary surgery with the attendant risk to the patient.

## Conflict of Interest Statement

The authors affirm that they have no conflict of interests to declare.

## REFERENCES

1. **Jacob M**, Barteczko K. Contribution to the origin and development of the appendices of the testis and epididymis in humans. *Anat Embryol (Berl)*. 2005;209(4):287–302.
2. **Pomajzl AJ**, Leslie SW. Appendix Testis Torsion. In: *StatPearls*. StatPearls Publishing; 2022.
3. **Kim JS**, Shin YS, Park JK. Clinical features of acute scrotum in childhood and adolescence: Based

- on 17years experiences in primary care clinic. *Am J Emerg Med*. 2018;36(7):1302–1303.
4. **Melekos MD**, Asbach HW, Markou SA. Etiology of acute scrotum in 100 boys with regard to age distribution. *J Urol*. 1988;139(5):1023–1025.
5. **Fujita N**, Tambo M, Okegawa T, *et al*. Distinguishing testicular torsion from torsion of the appendix testis by clinical features and signs in patients with acute scrotum. *Res Rep Urol*. 2017;9: 169–174.
6. **Mushtaq I**, Fung M, Glasson MJ. Retrospective review of paediatric patients with acute scrotum. *ANZ J Surg*. 2003;73(1–2):55–58.
7. **Qin KR**, Qu LG. Diagnosing with a TWIST: Systematic Review and Meta-Analysis of a Testicular Torsion Risk Score. *J Urol*. 2022;208(1): 62–70.
8. **Manohar CS**, Gupta A, Keshavamurthy R, *et al*. Evaluation of Testicular Workup for Ischemia and Suspected Torsion score in patients presenting with acute scrotum. *Urol Ann*. 2018;10(1):20–23.
9. **Foshee CH**. Torsion of the appendix testis: report of two cases. *J Am Med Assoc*. 1932; 99 (4):289–292.
10. **Kadish HA**, Bolte RG. A retrospective review of pediatric patients with epididymitis, testicular torsion, and torsion of testicular appendages. *Pediatrics*. 1998;102(1):73–76.
11. **Lev M**, Ramon J, Mor Y, *et al*. Sonographic appearances of torsion of the appendix testis and appendix epididymis in children. *J Clin Ultrasound*. 2015;43(8):485–489.

## Copyright Statement

The copyright of this manuscript is vested in this journal and in its publisher, the Association of Resident Doctors, University College Hospital, Ibadan.

This article is licensed under the Creative Commons Attribution-Non Commercial License 3.0 (CC BY-NC 3.0).